

Morphometric Studies on the Femorotibial Joint in Cattle

Abdalla Hifny, Kamal Eldin Hashem Abdalla, Yousria A. Abdel Rahman, Ruwaida Abdelmoaty Elhanbaly, Khaled Aly and Ahmed M. Kotb*

Department of Anatomy & Histology, Faculty of Veterinary Medicine, Assiut University, Assiut-71526, Egypt.

Received: 2 Jul. 2017, Revised: 25 Aug. 2017, Accepted: 28 Aug. 2017.

Published online: 1 Sep. 2017.

Abstract: Results obtained in this work reveals significant differences in the dimensions of the medial and lateral condyles of the femur. The condyles are convex in both directions. The cranoicaudal convexity of the medial condyle (116.92 ± 0.33 mm) is lesser than that of the lateral one (120.42 ± 1.16 mm). The mediolateral dimension of the medial condyle (68.65 ± 1.31 mm) is smaller than that of the lateral condyle (76.91 ± 0.05 mm). However the articular surface of the medial condyle of the tibia is larger than the lateral one.

The present finding reveals that the axial border of the menisci is thin and concave forming a U- shaped notch. Through this notch there is a communication between the proximal and distal compartments of the medial and lateral sacs of the femorotibial joint. The area of communication is large at the medial side.

The cruciate ligaments are two strong bands, cranial and caudal, situated mainly in the intercondyloid area of the femur between the two femorotibial synovial sacs. The cranial cruciate ligament is represented by two bands; the cranial and caudal.

The collateral ligaments of the femorotibial joint are long as they extend more distally from the margin of the articular surfaces, the medial one is longer than the lateral this leads to instability of movement.

Keywords: Femorotibial Joint – Cattle

1 Introduction

From the clinical point of view the stifle joint is very important; it includes the femoropatellar and femorotibial joints.

The bony architecture of the femur, patella and tibia contribute to the stability of the stifle joint, along with static and dynamic restraints of the ligaments, capsule and muscular crossing the joint (Goldblatt and Richmond, 2003). The femorotibial joint is the largest joint in the body, and is comprised of two condyloid articulations. The medial and lateral femoral condyles articulate with the corresponding tibial plateau. Intervening medial and lateral menisci serve to enhance the conformity of the joint (Goldblatt and Richmond, 2003). Ligaments play an important role in weight bearing and stability of the stifle joint.

2 Materials and Methods

The instability of the patella is affected by the shape of the trochlea of the femur, patella, menisci and ligaments.

This study was carried out on five stifle regions of adult cattle of local breeds. The specimens were collected from Assiut slaughterhouse. The studied specimens were clinically healthy and showed no evidence of marked bony abnormalities or degenerative diseases.

So the gross anatomical study of the femorotibial joint included:-

2.1 Morphological Study

The morphological features of different structures of the stifle joint were studied as following:

*Corresponding author e-mail: kotba@uni-greifswald.de

- 1- Shape and extension of the articular surfaces of the condyles of the femur and tibia as well as the menisci.
- 2- The line of attachment of the joint capsule and its pouches.
- 3- Shape, density, extension and area of attachment of the meniscal, cruciate and collateral ligaments.
- 4- The origin of the muscles related to the joint and their relations to the underlying pouches of the joint.

2.2 Morphometrical Study

Different measurements including the length, the width and thickness were carried out on the articular surfaces and ligaments of the femorotibial joint as follow:

- 1- Length and width of the articular surfaces of the femoral and tibial condyles.
- 2- Length, width and thickness of the menisci.
- 3- Length, width and thickness of the ligaments.

All the anatomical components were photographed and the dimensions were recorded using a digital caliper.

All measurements were statistically analysed using a one way-ANOVA.

Descriptive statistics are given as means \pm SD (standard deviation). The statistical analysis was carried out with Microsoft® Excel 2007 program. The data given in the form of tables.

The nomenclature used in the present work was adapted to the Nomina

Anatomica Veterinaria (2005) as well as the available literature.

3 Results

The femorotibial joint in cattle is formed between the condyles of the femur and the articular surface of the condyles of the tibia. Filling the space between the femur and tibia two crescentic fibrocartilage discs, the medial and lateral meniscus.

3.1 Articular Surface

3.1.1 Condyles of The Femur: (Table 1; Fig. 1)

The two condyles of the femur are directed caudodistally and separated from each other by wide and deep intercondyloid fossa. The medial condyle is large and ovoid in shape, its craniocaudal curvature is longer (116.92 ± 0.33 mm) than the mediolateral one (68.65 ± 1.31 mm). The lateral condyle is also ovoid in shape but is

placed at a slight higher level than the medial one. The craniocaudal curvature is longer (120.42 ± 1.16 mm) than the mediolateral curvature (76.91 ± 0.05 mm). It is separated cranially from the lateral ridge of the trochlea of the femur by a depression close to the articular margin, the extensor fossa. This fossa gives origin to the extensor digitorum longus and peroneus tertius.

3.1.2 Condyles of The Tibia: (Table 1; Fig. 2)

It was observed that the two condyles of the tibia in cattle are at the same level cranially and caudally and separated by the intercondyloid eminence. Each condyle has a gently saddle shaped articular surface, concave transversally and convex craniocaudally. The medial condyle measures about

93.41 ± 3.04 mm craniocaudally and 59.20 ± 1.81 mm transversally. The lateral condyle is slightly curved in both directions where its craniocaudal dimension is convex and reaches about 92.16 ± 0.1 mm and its mediolateral one is concave and reaches about 59.5 ± 0.19 mm.

The intercondyloid eminence is subdivided into medial and lateral intercondyloid tubercles. The medial tubercle is slightly higher than the lateral one and separated from each other by a central intercondyloid area. This area gives attachment to the caudal part of the cranial cruciate ligament. On the other hand, there are cranial and caudal intercondyloid areas which are located cranial and caudal to the intercondyloid eminence of the tibia. The condyles are separated caudally by the deep popliteal notch.

3.1.3 Menisci (Table 1; Figs. 3, 4, 5)

The medial and lateral menisci are fibrocartilage crescentic plate located between the condyles of the femur and tibia. Each meniscus covers the corresponding condyles of the tibia except its central part toward the intercondyloid eminence where it comes in contact with the corresponding condyle of the femur. Moreover, the lateral meniscus does not reach the border of the lateral condyle of the tibia caudolaterally but allows the tendon of origin of popliteus to pass over the tibial condyle and separating the lateral meniscus from the lateral collateral ligament of the femorotibial joint.

Each meniscus has two surfaces; proximal and distal, two borders; axial and abaxial and two extremities; cranial and caudal. The proximal surfaces of the menisci are adapted to the condyles of the femur therefore it is concave longitudinally and transversally. While that of the lateral one is deeply concave. The distal surface of the menisci is adapted to the condyles of the tibia, therefore they are nearly flattened.

The menisci have a thin concave axial border and a thick convex abaxial one. The axial border is thin and deeply concave forming U- shaped notch. The distance between the two borders reaches about 23.16 ± 0.03 mm and 25.84 ± 0.01 mm for the medial and lateral one respectively. The depth of the notch measures about 12.56 ± 0.02 mm at the medial meniscus and 12.46 ± 0.02 mm at the lateral meniscus. Therefore the communication between the proximal and distal compartments of the medial femorotibial sac is wide as well as the contact area between the medial condyle of the femur and that of the tibia is larger than that of the lateral one. The abaxial border is thick; its thickness varies cranially, at middle and caudally. For the medial meniscus it measures about 13.92 ± 0.03 , 8.52 ± 0.17 and 12.38 ± 0.04 mm respectively. While that of the lateral meniscus measures about 16.31 ± 0.03 , 12.71 ± 0.03 and 22.32 ± 0.02 mm respectively. In addition, there is a groove on the lateral aspect of the outer border of the lateral meniscus in which the tendon of origin of popliteal muscle is passed. The cranial and caudal extremities of the medial meniscus are narrower than those of the lateral one. Their width is about 21.82 ± 0.07 mm and 19.75 ± 0.06 mm respectively. The cranial extremity of the lateral meniscus is thinner and narrower than the caudal one and approximately 22.19 ± 0.02 mm and 27.85 ± 0.06 mm in width respectively.

3.2 Articular Capsule

The articular capsule consists of fibrous and synovial layer

3.2.1 Fibrous layer

The thickness of the fibrous layer decreases in thickness caudalwards. It attaches cranially with patellar ligaments and laterally with the collateral ligaments and the menisci of the femorotibial joint.

It is reinforced medially by the aponeurosis of sartorius and gracilius, laterally by the aponeurosis of the gluteobiceps and tensor fascia lata, proximally by the tendon of quadriceps and distally by the fascia of the leg.

3.2.2 Synovial layer

The synovial membrane of the femorotibial joint consists of medial and lateral femorotibial sacs. Each sac is partially divided into proximal and distal compartments by the corresponding meniscus. Both compartments communicate together axially through the axial concave border of the corresponding meniscus. The synovial membrane of the proximal compartment of the medial sac is attached to the margin of the articular surface of the medial condyle of the femur, but distally attaches peripherally to the proximal margin of the medial meniscus and axially to the inner margin of the medial condyle of the tibia. The joint cavity of the proximal compartment of the medial femorotibial sac

communicates proximally with the joint cavity of the femoropatellar joint. The synovial membrane of the distal compartment is attached to the distal margin of the medial meniscus and distally to the articular margin of the medial condyle of the tibia. The synovial membrane of the proximal compartment of the lateral sac is attached proximally to the articular margin of the lateral condyle of the femur, distally it is attached to the proximal margin of the abaxial border of the lateral meniscus. The synovial membrane of the distal compartment is attached proximally to the lower margin of the abaxial border of the lateral meniscus and distally to the margin of the lateral condyle of the tibia. The lateral femorotibial sac gives off two pouches. The lateral pouch extends under the tendon of origin of popliteal muscle. The cranial pouch extends distally through the extensor groove of the tibia between the muscle tibialis cranialis and the common tendon of origin of long digital extensor and peroneus tertius muscles.

3.3 Ligaments

3.3.1 Meniscal ligaments: (Table 2; Figs. 5, 6, 7, 8, 9)

3.3.1.1 Ligaments of The Medial Meniscus

-Cranial ligament of medial meniscus:

The cranial ligament of the medial meniscus is attached about the cranial half of its cranial extremity and extends laterally and slightly distally to end in a shallow cranial depression in the cranial intercondyloid area of the tibia. The tibial attachment is just cranial to the transverse genual and the cranial cruciate ligaments.

The cranial ligament of the medial meniscus reaches about 25.82 ± 0.12 mm long, 20.71 ± 0.04 mm wide and 3.46 ± 0.01 mm thick.

- Caudal ligament of medial meniscus:

The caudal ligament of the medial meniscus is attached about the caudal half of the caudal extremity of the medial meniscus. It is curved cranially to end in the caudal intercondyloid area of the tibia.

The caudal ligament of the medial meniscus reaches about 25.42 ± 0.04 mm long, 13.56 ± 0.05 mm wide and 4.71 ± 0.03 mm thick respectively.

3.3.1.2 Ligaments of The Lateral Meniscus

- Cranial ligament of lateral meniscus

The cranial ligament of the lateral meniscus is attached to the cranial half of the cranial extremity of the lateral meniscus and its adjacent outer border. It extends medially

and slightly distally on the lateral condyle of the tibia to terminate on the cranial intercondyloid area of the tibia cranial to the attachment of the cranial part of the cranial cruciate ligament.

The length, width and thickness of the cranial ligament of the lateral meniscus are 39.57 ± 0.05 , 13.05 ± 0.02 and 3.55 ± 0.01 mm respectively.

- Caudal ligament of lateral meniscus

The caudal ligament of the lateral meniscus is thin fibrous sheet. It is attached to the distal caudal part of the outer border of the lateral meniscus. This attachment is situated distal to the meniscal attachment of the meniscofemoral ligament. The caudal ligament of the lateral meniscus extends distally around the caudal margin of the lateral condyle of the tibia to end in the popliteal notch caudal to the distal portion of the caudal cruciate ligament.

The length, width and thickness of this ligament are 31.49 ± 0.19 mm, 11.82 ± 0.31 mm and 2.38 ± 0.28 mm respectively.

- Meniscofemoral ligament

The meniscofemoral ligament is the only ligament which attaches the lateral meniscus to the femur. It is thick well developed fibrous band, which attaches to the proximal caudal part of the abaxial border of the lateral meniscus. It extends obliquely proximomedially and incinuated into intercondyloid fossa of the femur to end in the proximomedial part of this fossa close to the medial condyle of the femur. The length, width and thickness of this ligament are about 50.92 ± 0.06 mm, 14.58 ± 0.08 mm and 6.55 ± 0.04 mm respectively.

- Transverse genual ligament

The transverse genual ligament is thin transverse band extends between the cranial ligament of the medial and lateral menisci. It is located between the cranial ligament of the medial meniscus cranially and the cranial part of the cranial cruciate ligament caudally.

3.3.2 Cruciate Ligaments: (Table 2; Figs. 5, 6, 7, 8, 9, 10, 11)

The cruciate ligaments are situated mainly in the intercondyloid fossa of the femur proximally and the intercondyloid area of the tibia distally and between the two synovial sacs of the femorotibial joint.

3.3.2.1 Cranial Cruciate Ligament

The cranial cruciate ligament arises by two parts; cranial and caudal. The small cranial part originates from a ridge

located in the cranial intercondyloid area just caudal to the area of attachment of the cranial ligament of the medial meniscus. The large caudal one is attached to the central intercondyloid area of the tibia. The two parts are directed proximally and caudally fusing together and pass lateral to the caudal cruciate ligament to end in the lateral wall of the intercondyloid fossa of the femur. It was observed that the cranial cruciate ligament is more twisted than the caudal one. Its length, width and thickness are about 62.24 ± 0.43 , 13.27 ± 0.12 and 7.38 ± 0.03 mm respectively.

3.3.2.2 Caudal Cruciate Ligament

The caudal cruciate ligament is attached to a large eminence on the medial aspect of the popliteal notch and extends proximally and cranially to end in the cranial part of the intercondyloid fossa of the femur.

Its length, width and thickness are 85.19 ± 0.07 , 9.74 ± 0.18 and 7.45 ± 0.02 mm respectively.

3.3.3 Collateral Ligaments

3.3.3.1 Medial Collateral Ligament: (Table 2; Hist. 1; Figs. 12)

The medial collateral ligament of the femorotibial joint is very long. It is represented by thick fibrous band. The medial collateral ligament extends from the medial epicondyle of the femur and directed vertically crossing the medial meniscus to end distal to the margin of the medial condyle of the tibia. The length, width and thickness of the medial collateral ligament are 106.90 ± 2.53 , 14.75 ± 0.16 and 2.08 ± 0.03 mm respectively.

3.3.3.2 Lateral Collateral Ligament: (Table 8; Hist. 1; Figs. 13, 14)

The lateral collateral ligament of the femorotibial joint is shorter than the medial one. It is represented also by thick fibrous band. It extends from the lateral epicondyle of the femur and directed vertically crossing the tendon of origin of popliteal muscle to end distal to the margin of the articular surface of the lateral condyle of the tibia. It was observed that there is a large subligamentary bursa between this ligament and lateral margin of the lateral condyle of the tibia. The length, width and thickness of the lateral collateral ligament are 97.07 ± 0.58 , 13.75 ± 0.51 and

3.74 \pm 0.03 mm respectively.

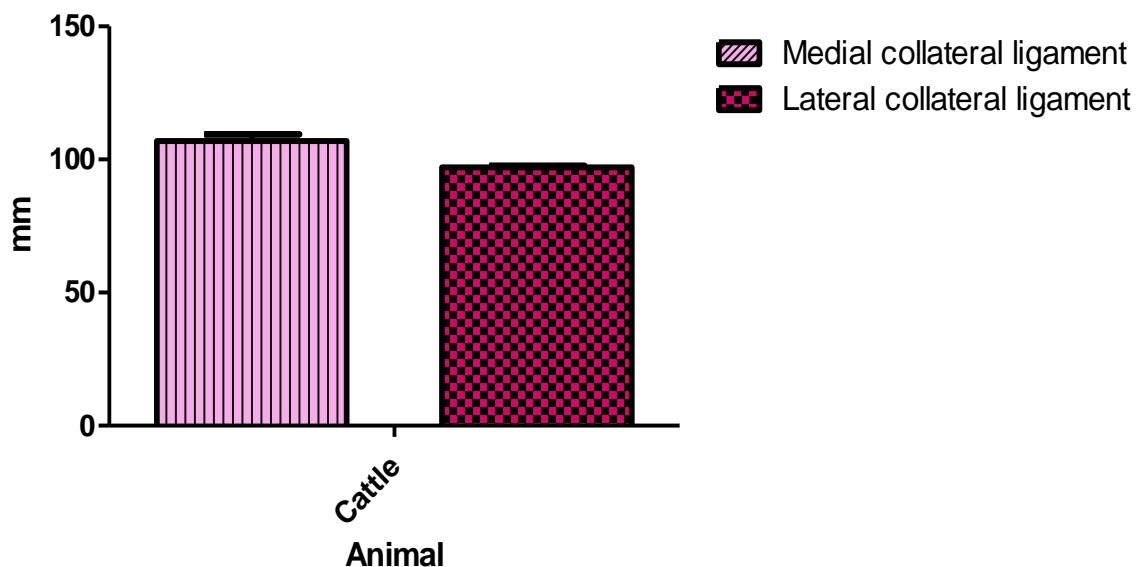
Table (1): Showing the dimensions of the articular surfaces of the femorotibial joint of cattle in mm.(Mean & S.E).

Items	Mean	S. E
A- Condyles of the femur		\pm 0.33
a -Medial condyle		\pm 1.31
- Craniocaudal dimension	116.92	
- Mediolateral dimension	68.65	\pm 1.16
b-lateral condyle		\pm 0.05
-Craniocaudal dimension	120.42	
-Mediolateral dimension	76.91	
B- Condyles of the tibia		
a- Medial condyle		\pm 3.04
- Craniocaudal dimension	93.41	\pm 1.81
- Mediolateral dimension	59.20	
b-lateral condyle		\pm 0.10
-Cranoicaudal dimension	92.16	\pm 0.19
-Mediolateral dimension	59.5	
C- Menisci		
1- Medial meniscus		
- Thickness of the abaxial border		\pm 0.03
*Cranially	13.92	
*At the middle	8.52	\pm 0.17
*Caudally	12.38	\pm 0.04
-Width of the cranial extremity	21.82	\pm 0.07
-Width of the caudal extremity	19.75	\pm 0.06
- Distance between two borders	23.16	\pm 0.03
- Depth of the notch	12.56	\pm 0.02
1- Lateral meniscus		
- Thickness of the abaxial border		\pm 0.03
*Cranially	16.31	
*At the middle	12.71	\pm 0.03
*Caudally	22.32	\pm 0.03
-Width of the cranial extremity	22.19	\pm 0.02
-Width of the caudal extremity	27.85	\pm 0.02
- Distance between two borders	25.84	\pm 0.06
- Depth of the notch	12.46	\pm 0.01
		\pm 0.02

Table (2): Showing the dimensions of the ligaments of the femorotibial joint of cattle in mm.(Mean &S.E).

Items	Mean	S. E
A- Meniscal ligaments		
I- Ligaments of medial meniscus		
1-cranial ligament		
-Length	25.82	±0.12
-Width	20.71	±0.04
-Thickness	3.46	±0.01
2-caudal ligament		
-Length	25.42	±0.04
-Width	13.56	±0.05
-Thickness	4.71	±0.03
II-Ligaments of lateral meniscus		
1-Cranial ligament		
-Length	39.57	±0.05
-Width	13.05	±0.02
-Thickness	3.55	±0.01
2-Caudal ligament		
-Length	31.49	±0.19
-Width	11.82	±0.31
-Thickness	2.38	±0.28
3-Meniscofemoral		
-Length	50.92	±0.06
-Width	14.58	±0.08
-Thickness	6.55	±0.04
C- Cruciate ligaments		
1- Cranial cruciate ligament		
-Length	62.24	±0.43
-Width	13.27	±0.12
Thickness	7.38	±0.03
2- Caudal cruciate ligament		
- Length	85.19	±0.07
-Width	9.74	±0.18
-Thickness	7.45	±0.02
D- Collateral ligaments		
1- Medial collateral ligament		
-Length	106.90	± 2.53
-Width	14.75	± 0.16
-Thickness	2.08	±0.03
2- Lateral collateral ligament		
- Length	97.07	±0.58
-Width	13.75	±0.51
-Thickness	3.74	±0.03

c-Lateral condyle of femur.



Histogram (1): Showing the length of the medial and lateral collateral ligaments of the Femorotibial joint in cattle.

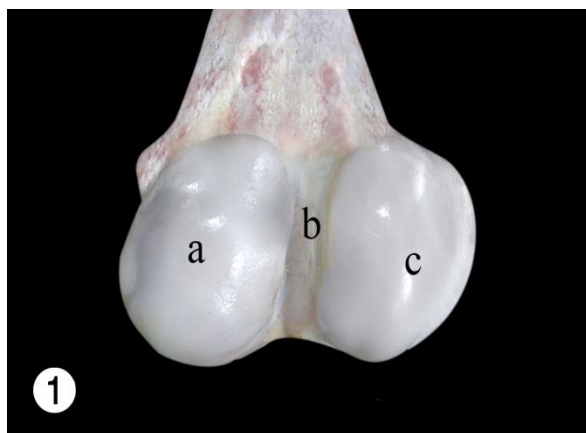


Fig. (1): Photograph of distal extremity of right femur of cattle. Caudal view.
 a-Medial condyle of femur
 b-Intercondyloid fossa

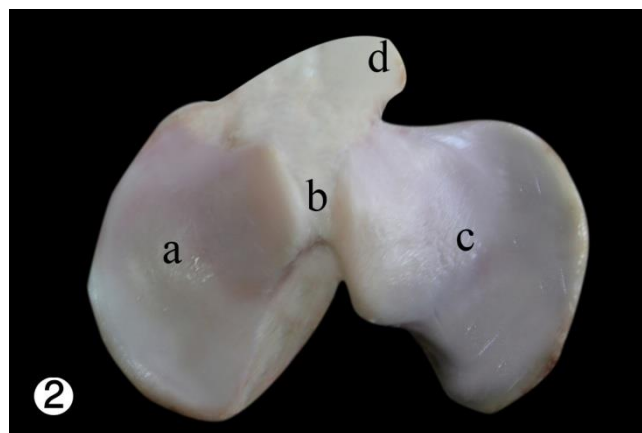


Fig. (2): Photograph of proximal extremity of right tibia of cattle. Proximal view.
 a-Medial condyle of tibia
 b-Central intercondyloid area

c-Lateral condyle of tibia
d-Tibial tuberosity.

b-Abaxial border of lateral meniscus
c-Groove on the abaxial border of the lateral meniscus for the popliteus.

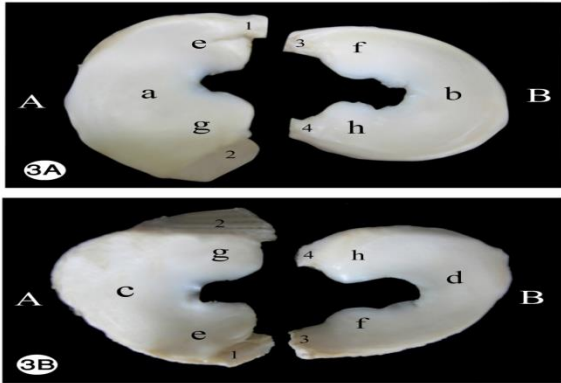


Fig. (3A&B): Photograph of menisci of left stifle of cattle.

A- Lateral meniscus B- Medial meniscus
a- Proximal surface of lateral meniscus
b- Proximal surface of medial meniscus
c- Distal surface of lateral meniscus
d- Distal surface of medial meniscus
e- Cranial extremity of lateral meniscus
f- Caudal extremity of medial meniscus
g- Caudal extremity of lateral meniscus
h- Caudal extremity of medial meniscus.
1- Cranial ligament of lateral meniscus
2- Menisiofemoral ligament
3- Cranial ligament of medial meniscus
4- Caudal ligament of medial meniscus.

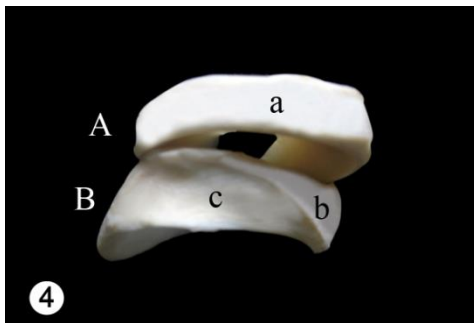


Fig. (4): Photograph of menisci of right stifle joint of cattle. Lateral view.
A-Medial meniscus B-Lateral meniscus
a-Abaxial border of medial meniscus

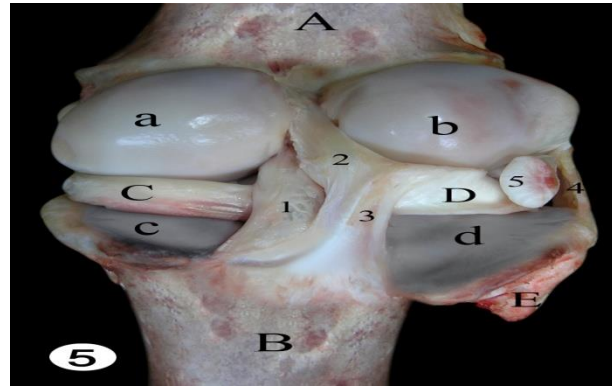


Fig. (5): Photograph of right femorotibial joint of cattle. Caudal view.

A-Femur B-Tibia C- Medial meniscus
D- Lateral meniscus E- Fibula

a-Medial condyle of femur
b-Lateral condyle of femur
c-Medial condyle of tibia
d- Lateral condyle of tibia
1-Caudal cruciate ligament
2-Menisiofemoral ligament
3-Caudal ligament of lateral meniscus
4-Lateral collateral ligament
5-Tendon of origin of popliteus.

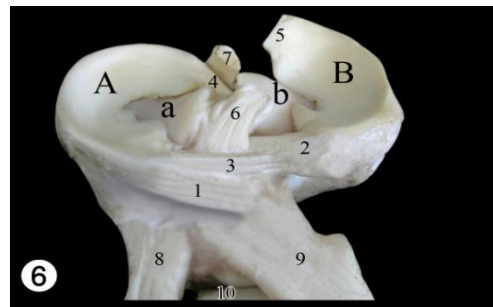


Fig. (6): Photograph of proximal extremity of tibia with the menisci and their ligamental attachments of left stifle of cattle.

A- Medial meniscus B- Lateral meniscus
a- Medial condyle of tibia
b-Lateral condyle of tibia.
Cranial ligament of medial meniscus
Cranial ligament of lateral meniscus
Transverse genu ligament
Caudal ligament of medial meniscus

Menisofemoralligament
 Cranial cruciate ligament
 Caudal cruciate ligament
 Medial patellar ligament
 Lateral patellar ligament
 Intermediate patellar ligament.

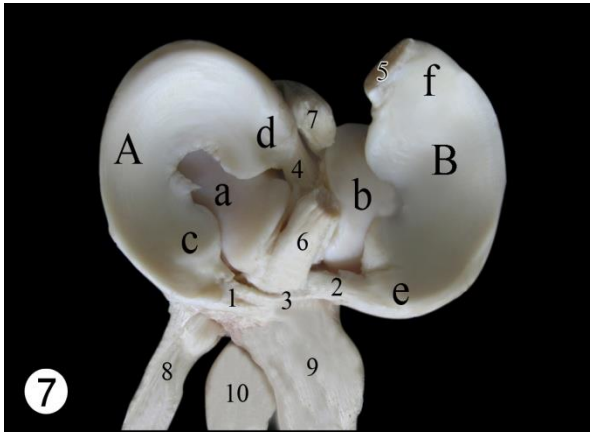


Fig. (7): Photograph of left proximal extremity of tibia with menisci and their ligamental attachments of cattle.

A-Medial meniscus B-Lateral meniscus
 a-Medial condyle of tibia
 b-Lateral condyle of tibia
 c-Cranial extremity of medial meniscus
 d-Caudal extremity of medial meniscus
 e-Cranial extremity of lateral meniscus
 f-Caudal extremity of lateral meniscus.
 1-Cranial ligament of medial meniscus
 2-Cranial ligament of lateral meniscus;
 3-Transverse genual ligament
 4- Caudal ligament of medial meniscus
 5- Menisofemoralligament
 6-Cranial cruciate ligament
 7-Caudal cruciate ligament
 8-Medial patellar ligament;
 9-Lateral patellar ligament
 10- Intermediate patellar ligament.

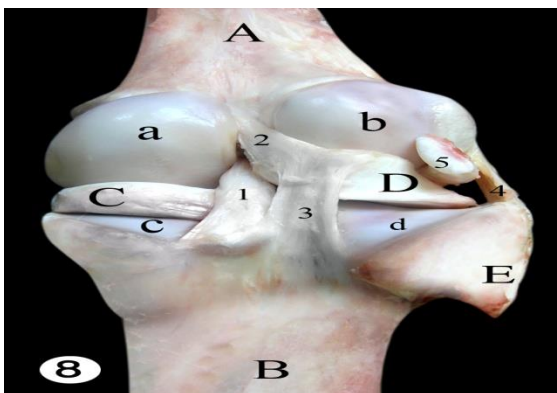


Fig. (8): Photograph of right femorotibial joint of cattle. Caudal view.

A-Femur B-Tibia
 C- Medial meniscus D- Lateral meniscus
 E- Fibula

a-Medial condyle of femur
 b-Lateral condyle of femur
 c-Medial condyle of tibia
 d- Lateral condyle of tibia
 1-Caudal cruciate ligament
 2-Menisofemoralligament
 3-Caudal ligament of lateral meniscus
 4-Lateral collateral ligament
 5-Tendon of origin of popliteus muscle.

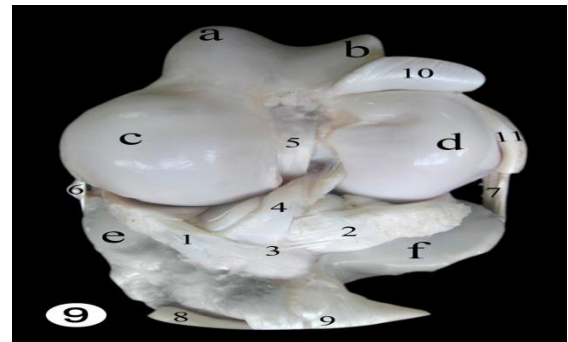

Fig. (9): Photograph of the distal extremity of the femur and the proximal extremity of the tibia and their ligamental attachments of left stifle joint of cattle. The capsules are removed.

a-Medial ridge of trochlea
 b- Lateral ridge of trochlea
 c- Medial condyle of femur
 d- Lateral condyle of femur
 e- Medial condyle of tibia
 f- Lateral condyle of tibia.
 1-Cranial ligament of medial meniscus
 2- Cranial ligament of lateral meniscus
 3-Transverse genual ligament
 4-Cranial cruciate ligament (Twisted)
 5-Caudal cruciate ligament
 6-Medial collateral ligament
 7-Lateral collateral ligament
 8-Intermediate patellarligament
 9-Lateral patellar ligament
 10-Common tendon of origin of long digital extensor & peroneaustertius muscles
 11-Tendon of origin of popliteus muscle.

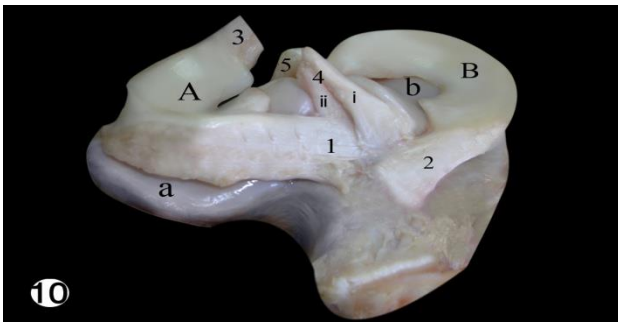


Fig. (10): Photograph of proximal extremity of right tibia of cattle and its ligamentous attachments.

- A- Lateral meniscus B- Medial meniscus
 a- Lateral condyle of tibia b- Medial condyle of tibia.
 1-Cranial ligament of lateral meniscus
 2-Cranial ligament of medial meniscus;
 3-Meniscofemoral ligament
 4-Cranial cruciate ligament
 i-Cranial part of the cranial cruciate ligament
 ii-Caudal part of the cranial cruciate ligament
 5- Caudal cruciate ligament.

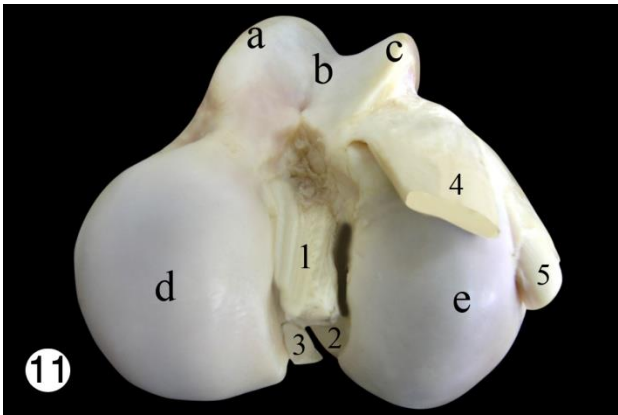


Fig. (11): Photograph showing ligaments and tendons attached to the left distal extremity of femur of cattle. Distal view.

- a-Medial ridge of trochlea of femur
 b-Groove of trochlea of femur;
 c-Lateral ridge of trochlea of femur
 d-Medial condyle of femur;
 e- Lateral condyle of femur
 1-Caudal cruciate ligament
 2-Cranial cruciate ligament
 3-Meniscofemoral ligament;
 4-Common tendon of origin of long digital extensor & peroneaustertius muscles
 5-Tendon of origin of popliteus muscle.

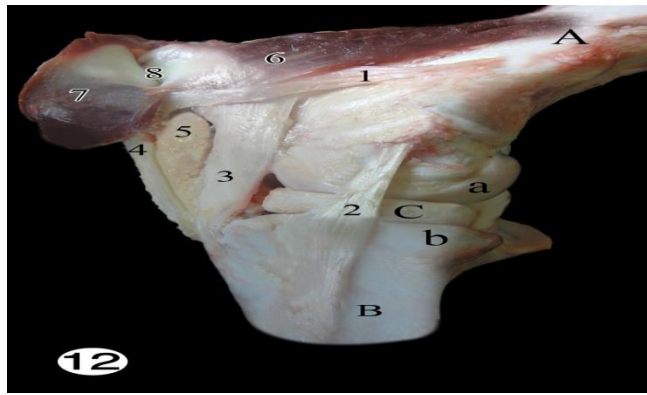


Fig. (12): Photograph of right stifle joint of cattle. Medial view. The capsules are removed.

- A- Femur B- Tibia C-Medial meniscus
 a-Medial condyle of femur
 b-Medial condyle of tibia.
 1-Medial femoropatellar ligament
 2-Medial collateral ligament
 3-Medial patellar ligament
 4-Intermediate patellar ligament
 5-Corpus adiposuminfrapatellare
 6-Intermediate vastus muscle
 7-Medial vastus muscle
 8-Subtendinous bursa of the medial vastus muscle.

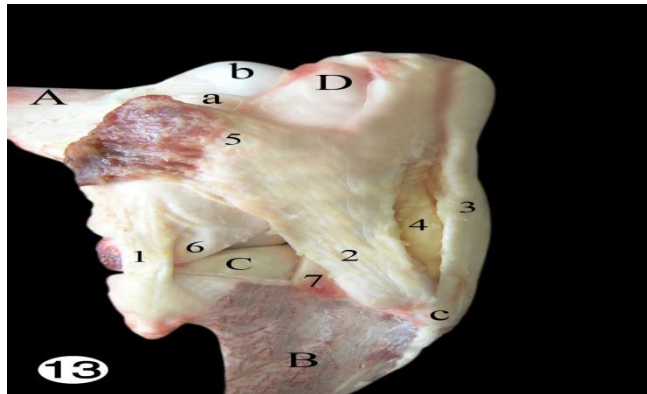


Fig. (13): Photograph of right stifle joint of cattle. Lateral view. The capsules are removed.

- A- Femur B- Tibia
 C-Lateral meniscus D-Patella
 a-Lateral ridge of trochlea
 b-Medial ridge of trochlea
 c-Tibial tuberosity.
 1-Lateral collateral ligament
 2-Lateral patellar ligament
 3-Intermediate patellar ligament;
 4-Corpus adiposuminfrapatellare
 5-Tendon of insertion of gluteobiceps
 6-Tendon of origin of popliteal muscle
 7- Common tendon of origin of long digital extensor & Peroneaustertius muscles

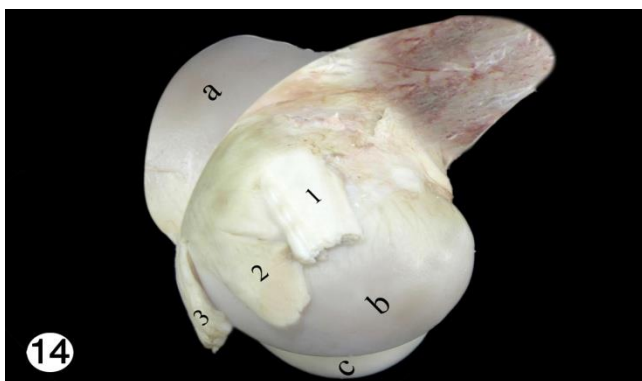


Fig. (14): Photograph of left distal extremity of femur of cattle. Lateral view.

- a-Lateral ridge of trochlea of femur
- b-Lateral condyle of femur;
- c- Medial condyle of femur.
- 1-Lateral collateral ligament
- 2-Tendon of origin of popliteal muscle
- 3-Common tendon of origin of long digital extensor &
- 4- peroneus tertius muscles.

4 Discussion

The stifle is a modified hinge joint that must allow flexion and rotation, yet provide complete stability and control under a great range of loading conditions. The stifle consists of two joints, femoropatellar and femorotibial joints.

The bony architecture of the femur, tibia and patella contribute to the stability of the stifle joint, along with static and dynamic restraints of the ligaments, capsule and musculature crossing the joint (Simon et al., 2000).

The stifle joint is a modified hinge joint compounded of paired femorotibial and single femoropatellar articulation (Dyce and Wensing, 1971). The two articulations are interdependent in that the patella is firmly connected to the tibia by ligamentous tissue so that any movement between the femur and the tibia also occurs between the patella and femur (Evans, 1993).

The femorotibial joint is the largest joint in the body and is composed of two condyloid articulations. The medial and lateral femoral condyles articulate with the corresponding tibial condyles. Intervening medial and lateral menisci serve to enhance the conformity of the joint.

The present study denotes that the two condyles of the femur of the examined cattle are ovoid in shape and slightly oblique in accordance with those given by Dyce and Wensing (1971) in domestic animals, Raghavan (1964) in the ox and Sisson (1975) in the horse.

In agreement with Sisson (1975) in the domestic animals the articular surface of the tibia consists of two condyles which are saddle shaped. According to the available literature, there are great differences in the form of the tibial condyles in different animals, they are flat and have a gently undulating surface as mentioned by Nickel et al. (1986); and Dyce et al. (1996). In the camel (Morcos,

1955) and dog (Evans, 1993) the medial condyle is nearly semicircular or oval while the lateral one is nearly saddle or circular respectively.

The general morphological features of the menisci entering in the formation of the femorotibial joint of cattle show great resemblance to those of the ox (Raghavan, 1964), camel (Morcos, 1955), horse (Sisson, 1975) and sheep (May, 1970).

The present finding reveals that the axial border of the menisci is thin and concave forming a U-shaped notch. Through this notch there is a communication between the proximal and distal compartments of the medial and lateral sacs of the femorotibial joint. Also there is a direct contact between the condyles of the tibia and femur.

Sisson (1975) and Fransson and Spurgeon (1992) stated that the menisci in domestic animals help to keep the joint congruent, allow greater range or variety of movement and also diminish concussion. However, Skerritt and McLelland (1984) suggested that the main function of the menisci is believed to provide additional surfaces on which the synovial fluid can exert a lubricating action.

In the present work it can be observed that the medial and lateral compartments of the femorotibial joint have an intervening meniscus located between the femur and tibia. Grossly the menisci are peripherally thick and convex and centrally taper to a thin free margin. The meniscal surfaces conform to the femoral and tibial contours. The medial meniscus is semicircular; the caudal extremity is wider than the cranial extremity. The cranial extremity is attached to the cranial intercondyloid area in front of the cranial cruciate ligament by the cranial ligament. This attachment is to the cranial surface of tibial condyles.

The caudal extremity of the medial meniscus is firmly attached to the caudal intercondyloid area of the tibia by the caudal ligament of the medial meniscus cranial and medial to the caudal cruciate ligament tibial attachment side. Peripherally the medial meniscus is attached to the medial collateral ligament.

The lateral meniscus is semicircular and covers a large portion of the tibial condyle than the medial meniscus. The lateral meniscus has cranial and caudal meniscal ligaments anchored to the tibia. The cranial ligament of the lateral meniscus attaches its cranial extremity to the cranial intercondyloid area between the two parts of the cranial cruciate ligament. The caudal one attaches its caudal extremity to the popliteal notch. The lateral meniscus is loose peripherally as it is separated from the lateral collateral ligament by the tendon of origin of the popliteal muscle. In addition the lateral meniscus has an attachment through the meniscofemoral ligament to the medial condyle of the femur. In cattle, it was observed that a transverse genu ligament connects the cranial extremities of both menisci.

When the stifle joint is flexed the menisci move caudally. Caudal motion of the medial meniscus is guided by its attachment to the medial collateral ligament and semimembranosus, whereas cranial translation is caused by the push of the cranial femoral condyle (Simon et al.,

2000). The lateral meniscus is stabilized and motion guided by the popliteus tendon and menisiofemoral ligament (Heller and Langman, 1964; Staubli and Birrer, 1990).

In bovine the menisci glide forwards over the tibia as the femoral condyles roll upon them in extension and the restriction of their movement imposed by the meniscal ligaments is important brake upon straightening the joint (Dyce and Wensing, 1971).

From the morphological point of view, the movement between the menisci and the tibia is a gliding movement due to their articular surfaces is nearly flat. As the articular surfaces of the femur and menisci are condylar in shape, therefore this joint is a hinge joint. The menisci are fixed on the tibia by the meniscal ligaments. Therefore the femur moves on the menisci which are fixed on the tibia.

The present investigation reveals that the cruciate ligaments are two strong bands, cranial and caudal, situated mainly in the intercondyloid area of the femur between the two femorotibial synovial sacs. The cruciate ligaments are named according to their tibial attachment. The same findings were described in ox (Habel, 1955; Raghavan, 1964), camel (Morcos, 1955), horse (Sisson, 1975) and sheep (May, 1970).

In the present work the cranial cruciate ligament arises from the central intercondyloid area and extends proximally and caudally to terminate on the lateral wall of the intercondyloid fossa of the femur. These results are similar to that of the above mentioned animals. The present work revealed that the cranial cruciate ligament represented by two bands, cranial and caudal. The cranial band originates from a ridge located caudal to the area of attachment of the cranial ligament of the medial meniscus. The caudal band is attached to the central intercondylar area of the tibia. The two bands pass proximally and caudally fusing together and pass lateral to the caudal cruciate ligament to the above mentioned termination. While, Dueland *et al.* (1982) in the dog observed that the cranial cruciate ligament has two origins from the lateral condyle of the femur. On the other hand, in dog and man (Rooster *et al.*, 2006;

Goldblatt and Richmond, 2003) the cranial cruciate ligament is arranged anatomically and functionally into distinct bands, craniomedial and caudolateral.

In agreement with those described by Raghavan (1964) in ox, Sisson (1975) in horse and Skerritt and McLelland (1984) in domestic animals the caudal cruciate ligament is attached to a large eminence on the medial aspect of the popliteal notch. It extends proximally and cranially medial to the cranial cruciate ligament to end on the cranial part of the intercondyloid fossa of the femur. However, in domestic animals the ligament originates from the intercondylar fossa of the medial condyle of the femur and insert either on the caudal intercondylar area of the tibia (Shively, 1985) or on the tibia (Nickel *et al.*, 1986).

On the other hand, the cranial cruciate ligament appears to be arranged in two bands both cranial and caudal in canine (Rooster *et al.*, 2006) or anteriolateral and posteriolateral in man (Goldblatt and Richmond, 2003).

Dyce *et al.* (1996) in domestic animals suggested that the cruciate ligaments assist the collateral ligaments in opposing rotation as well as medial and lateral deviation of the leg. They are often susceptible to injury when tautened. The cranial cruciate ligament named for relative position of its tibial attachment, is therefore at highest risk when strained in overextension of the joint, its rupture allows abnormally free forward displacement of the tibia in relation to the femur (the cranial drawer sign). The caudal cruciate ligament is at greatest risk in the flexed position of the joint and its rupture allows excessive caudal displacement of the tibia (the caudal drawer sign). Various surgical techniques for the restoration or replacement of these ligaments use fascial or artificial substitutes. However, Rooster *et al.* (2006) in their study on the cruciate ligaments concluded that the cranial cruciate ligament controls

cranial drawer motion, whereas the caudal cruciate ligament acts as a major stabilizer against caudal motion. Furthermore the latter ligament is considered to fine tune normal stifle joint kinematics.

The stifle joint is held in apposition by a medial and a lateral collateral ligament on either side (Fransson and Whitten, 1981).

The present finding reveals that in cattle as in ox (Habel, 1955; Raghavan, 1964), horse (Bradley and Grahame, 1946; Sisson, 1975) and sheep (May, 1970), the medial collateral ligament originates from the medial epicondyle of the femur. It extends distally and blends with the joint capsule, forming a strong attachment to the capsule and medial meniscus. It terminates on the tibia distal to the margin of the medial condyle of the tibia. Skerritt and McLelland (1984) stated that the medial collateral ligament has superficial and deep parts; the deep part is closely attached to the joint capsule where the capsule joins the medial meniscus. In the present work as well as in the dog (Vasseur and Arnoczky, 1981; Evans, 1993), as the medial collateral ligament passes over the tibial condyle a bursa is interposed between the ligament and the bone.

In the present work the lateral collateral ligament has an origin from the lateral epicondyle of the femur. In cattle it terminates on the lateral condyle of the tibia. On the other hand, the lateral collateral ligament of the femorotibial joint of the domestic animals (Nickel *et al.*, 1986) and dog (Evans, 1993) ends distally on the lateral of the tibia and also the head of the fibula. The fibular branch is particularly well developed in carnivores.

The present investigation reveals that as the ligament crosses the joint cavity it passes over the tendon of origin of the popliteal muscle.

The collateral ligaments worked together with cruciate ligaments to limit internal rotation. In extension the collateral ligaments were the primary check against internal rotation, in flexion the cruciate were the primary restraint against internal rotation of the tibia. External rotation was limited only by the collateral ligaments in both flexion and

extension. Vasseur and Arnoczky(1981) and Skerritt and McLelland (1984) added that the ligaments are also important in presenting lateral and medial stability.

The collateral ligaments must be attached close to the margin of the articular surface to fix the direction of movement in extension and flexion. The present work shows that the collateral ligaments are long as they extend more distally from the margin of the articular surfaces. Therefore, this leads to instability of movement extension and flexion, particularly in buffalo.

References

- [1] Bradley, O. C. and Grahame, T. (1946):The topographical anatomy of the limbs of the horse. 2nd Ed.W. Green & Son Ltd.Edinburgh.
- [2] Dueland, R. D.; Sisson, S. and Evans, H. E. (1982):Aberrant origin of the cranial cruciate ligament mimicking an osteochondral lesion radiographically: a case history report.Vet. Radiol., 23: 175- 177.
- [3] Dyce, K. M.; Sack, W. O. and Wensing, C. J. G. (1996):Text book of veterinary anatomy.2nd Ed.W. B. Saunders Co.Philadelphia. London. Toronto. Montreal. Sydney. Tokyo.
- [4] Dyce, K. M. and Wensing, C. J. G. (1971):Essentials of bovine anatomy. Lea &Febiger. Philadelphia.
- [5] Evans, H. E. (1993):Miller's anatomy of the dog. 3rd Ed.W. B. Saunders Co.Philadelphia. London. Toronto. Montreal. Sydney.Tokyo.
- [6] Farahmand, F.; Tahmasbi, M. N. and Amis, A. (2004):29-The contribution of the medial retinaculum and quadriceps muscles to patellar lateral stability – an invitro study.The knee, 11: 89 - 94.
- [7] Frandson, R. D. and Whitten, E. H. (1981):Anatomy and physiology of farm animals. 3rd Ed.Lea&Febiger. Philadelphia.
- [8] Galland, O.; Walch, G.; Dejour, H. and Carret, J. P. (1990): An anatomical and radiological study of the femoropatellar articulation.Surg. Radiol. Anat., 12: 119 - 125.
- [9] Habel, R. E. (1955):42-Guide to the dissection of the cow. J. W. Edwards, publisher. Michigan.
- [10] Heller, L. and Langman, J. (1964): The meniscofemoral ligaments of the human knee.J. Bone Joint Surg., 46: 307-313.
- [11] May, N. D. S. (1970):The anatomy of the sheep.3rd Ed.University of Queensland Press,Brisbane. Australia.
- [12] Morcos, B. M. (1955):The anatomical study of the joints of the limbs of the camel. M. D.Vet. (Thesis).Fac. Vet. Med.Cairo University.
- [13] Nickel, R.; Schummer, A.; Seiferle, E.; Wilkens, H.; Wille, K-H. and Frewein, J. (1986):The locomotor system of the domestic mammals.In Nickel, R.; Schummer, A. and Seiferle, E.The anatomy of domestic animals. Verlag Paul Parey, Berlin. Hamburg.
- [15] Nomina Anatomica Veterinaria (2005):Published by the Editorial Committee. 5th Ed.Hannover. Columbia.Gent.Sapporo.
- [16] Raghavan, D. (1964):Anatomy of the ox with comparative notes on the horse,dog and fowl.1st Ed.Indian Council of Agricul. Research New Delhi.
- [17] Rooster, H. D.; Brun, T.D. and Bree, H. V. (2006): Morphologic and functional features of the canine cruciate ligaments.Vet. Surg., 35: 769- 780.
- [18] Shively, M. J. (1985):Veterinary anatomy basic, comparative and clinical.Texas A & M University Press College Station.
- [19] Simon, S. R.; Alaranta, H.; An, K.N. and et al. (2000):Kinesiology, in Buckwalter, J. A.; Einhorn, T. A. and Simon, S.R. (eds):Orthopaedic basic science: Biology and Biomechanics of the musculoskeletal system. 2nd Ed.Am. Acad. of Orthop. Surg., 730- 827.
- [20] Sisson, S. (1975):Synesmology.In Sissons, S. and Grossman, J. D.:The anatomy of the domestic animals. 5th Ed. Rev. by Getty, R.W. B. Saunders Co. Philadelphia. London. Toronto.
- [21] Skerrit, G. C. and McLelland, J. (1984):An introduction to the functional anatomy of the limbs of the domestic animals.John Wright & Sons. Bristol. England.
- [22] Staubli, H. U. and Birrer, S. (1990):The popliteus tendon and its fascicles at the popliteal hiatus: Gross anatomy and functional arthroscopic evaluation with and without anterior cruciate ligament deficiency.Arthroscopy, 6:209- 220.
- [23] Vasseur, P. B. and Arnoczky, S. P. (1981): Collateral ligaments of the canine stifle joint. Anatomical and functional analysis.Am. J. Vet. Res., 42: 1133

